BSAVA BRITISH SMALL ANIMAL VETERINARY ASSOCIATION

JSAP JOURNAL OF SMALL ANIMAL PRACTICE

PAPER

Computed tomography imaging characteristics of canine nasal chondrosarcoma

R. Jania[1,*], B. Boudreaux*, I. Langohr†, J. Looper* and N. Rademacher*

*Department of Veterinary Clinical Sciences, Louisiana State University, School of Veterinary Medicine, Baton Rouge, Louisiana 70803, USA
†Department of Pathobiological Sciences, Louisiana State University, School of Veterinary Medicine, Baton Rouge, Louisiana 70803, USA

[1]Corresponding author email: rjania@lsu.edu

Objectives: To describe the CT appearance of canine nasal chondrosarcoma and compare calcification patterns with those described in humans.

Materials and Methods: CT examinations of dogs with biopsy confirmed nasal chondrosarcoma were retrospectively reviewed and evaluated, including description of calcification patterns.

Results: Major findings are consistent with the previously described CT appearance of canine nasal tumours. Additionally, calcification patterns described as features of human nasal chondrosarcomas were also identified.

Clinical Significance: Findings may help prioritise differential lists of destructive nasal masses seen on CT in dogs.

Journal of Small Animal Practice (2019)
DOI: 10.1111/jsap.13064

Accepted: 1 July 2019

INTRODUCTION

Nasal tumours account for 1 to 2% of reported canine neoplasms (MacEwen *et al.* 1977). Approximately one-third of these tumours are sarcomas, which are generally locally invasive with a relatively lower metastatic rate (13.5%) than other types of nasal tumours (Patnaik 1989). Chondrosarcomas are characterised by the production of a primarily chondroid tumour matrix (Rozeman *et al.* 2006). It is the second most common primary bone tumour in dogs (Brodey *et al.* 1974) and approximately 30% of these occur in the nasal cavity (Popovitch *et al.* 1994). In a population of 285 canine sinonasal neoplasms, 12% (34/285) were chondrosarcoma (Patnaik *et al.* 1984) and chondrosarcoma comprised 49% of nasal sarcomas in a population of 86 dogs with sinonasal neoplasms treated with radiotherapy (Sones *et al.* 2013). In human medicine, chondrosarcoma is also the second most common primary bone tumour (Burningham *et al.* 2012) and approximately 4% arise from the facial bones (Inwards 2007). Radiographic and CT imaging findings suggestive of sarcomas originating from bone or cartilage have been extensively described based on the appearance of the tumour matrix. Calcification patterns of chondroid matrix tumours (*i.e.* chondrosarcomas) are described as rings-and-arcs, popcorn, focal stippled or flocculent (Murphey *et al.* 2003). The calcification patterns seen with osteoid matrix in aggressive bone tumours (*i.e.* osteosarcoma) are different and described as cloud-like and amorphous (Roche *et al.* 2002).

In dogs, CT features have been correlated with nasal neoplasia, including destruction of ethmoid bones, destruction of bones surrounding the nasal cavities, abnormal soft tissue in the retrobulbar space, hyperostosis of the lateral maxilla and areas of increased density within abnormal soft tissues (Thrall *et al.* 1989). Potential defining characteristics have been suggested based on the location of the lesion and degree of bone lysis. Carcinomas tend to occur in the mid-to-caudal nasal cavity, nasal lymphoma is often centred on the ventral nasal meatus and neuroendocrine tumours are generally adjacent to the cribriform plate (Dernell *et al.* 2007). Additionally, carcinomas and sarcomas are reported to be more likely to cause lysis of dense bones (Dernell *et al.* 2007). Similar findings occur in imaging of human sinonasal tumours, for which location and degree of bone lysis are often used to characterise tumour types; radiographic and CT imaging findings suggestive of sarcomas originating from bone or cartilage can be based on the appearance of the tumour matrix.

The purpose of this study is to describe CT imaging features of confirmed nasal chondrosarcoma in a series of dogs and identify calcification patterns potentially suggestive of nasal chondrosarcoma.

MATERIALS AND METHODS

This retrospective study included dogs that presented for evaluation of nasal disease to a university veterinary teaching hospital from January 2005 to August 2016. Inclusion criteria were determined by one board-certified radiologist and one board-certified oncologist. Animals were included if they underwent a precontrast and postcontrast CT examination of the head and had a histologic diagnosis of nasal chondrosarcoma.

Medical records were retrieved, and clinical findings were recorded. Data included age, breed, sex, neuter status, presenting clinical signs and duration, results of complete blood count, serum biochemistry profile, urinalysis, cytology of mandibular lymph nodes, histology of the nasal mass, thoracic radiographic findings and abdominal ultrasound findings, when available. Thoracic radiographs were acquired in right and left lateral, ventral-dorsal and dorso-ventral if the patient was compliant, before CT imaging. Radiographs were obtained with digital radiography (Eklin EDR 6; Sound-Eklin) using a standard exposure chart. Abdominal ultrasounds were performed using one of two ultrasound machines (Philips iU22; Philips with a microconvex 5 to 8 MHz transducer or Aplio 300; Toshiba Medical with a microconvex 8 to 11 MHz transducer).

CT of the head was performed with a 16-slice multidetector-row scanner (GE Lightspeed; GE Medical Systems) with dogs under general anaesthesia and positioned in sternal recumbency. Precontrast and postcontrast helical transverse images were acquired with a slice thickness between 1 and 4 mm and two reconstruction algorithms in soft tissue and bone. Postcontrast series were obtained after injection of 2.2 mL/kg of intravenous iopromide (300 mg/mL) through a peripheral catheter at a rate of 2 mL/second. Images were retrospectively reviewed by one board-certified radiologist and the primary author, each using personal computer-based diagnostic work stations (using picture archiving and communication system) within the hospital using digital imaging and communications in medicine software (eFilm; Merge Healthcare). Neither were blinded to the histologic diagnoses. Images were reviewed for characteristics used in the CT-based modified Adams tumour staging criteria (see Table 1) and five additional characteristics: (1) location within the nasal cavity; (2) postcontrast homogeneity

Table 1. Summary of the CT-based modified Adams tumour staging system criteria (Adams et al. 2008)

Stage	Criteria
1	Confined to one nasal passage, paranasal sinus or frontal sinus, with no bone involvement beyond turbinates
2	Any bony involvement (beyond turbinates), but no evidence of orbital, subcutaneous or submucosal masses
3	Orbital involvement or nasopharyngeal, subcutaneous or submucosal masses
4	Tumour causing lysis of the cribriform plate

Table 2. Summary of the CT findings in 11 chondrosarcomas including the CT-based modified Adams tumour staging system criteria and additional descriptive criteria

Case no.	Predominant location	Bilateral	Site involvement	Behaviour	Margin	Contrast enhancement	Mineralisation	Modified Adams stage	Lymph node involvement
1	Left nasal cavity	Y	CP, RB, HP	Expansile	Partially well-defined	Diffuse, heterogeneous	Popcorn	4	N
2	Left ventrocaudal nasal cavity	N	CP	Destructive/space occupying	Ill-defined	Rim and septal enhancement	N	4	N
3	Left nasal cavity	Y	CP, RB, HP	Expansile	Partially well-defined	Diffuse, heterogeneous	Popcorn	4	N
4	Left caudal nasal cavity	N	–	Destructive/space occupying	Ill-defined	Peripherally and diffuse, heterogeneous	N	1	N
5	Right nasal cavity	Y	CP, FS, RB	Destructive/space occupying	Partially well-defined	Diffuse, heterogeneous	Popcorn	4	N
6	Right nasal cavity	Y	NB, CP, FS, RB	Expansile	Well-defined	Diffuse, heterogeneous	Popcorn	4	Mild ipsilateral retropharyngeal
7	Right nasal cavity	Y	CP, RB	Expansile	Well-defined	Diffuse, heterogeneous	Popcorn	4	N
8	Right rostral nasal cavity	N	HP	Destructive/space occupying	Partially well-defined	Diffuse, heterogeneous	Ring	3	N
9	Right nasal cavity	Y	–	Destructive/space occupying	Partially well-defined	Diffuse, heterogeneous	N	2	N
10		Y	NB, CP, FS, RB	Destructive/space occupying	Partially well-defined	Diffuse, heterogeneous	Ring	4	N
11	Left nasal cavity	Y	NB, CP, FS, RB	Destructive/space occupying	Partially well-defined	Diffuse, heterogeneous	Popcorn	4	N

CP Cribriform plate, RB Retrobulbar space, HP Hard palate, FS Frontal sinus, NB Nasal bone

and attenuation values of the mass; subjectively and by measuring attenuation Hounsfield Unit (HU) values; (3) presence and characterisation of calcification within the tumour; (4) tumour margin behaviour and appearance and (5) appearance of mandibular and retropharyngeal lymph nodes (normal or enlarged and contrast enhancement characteristics).

"Ring-and-arc" calcification was defined as well-defined areas of calcification in the shape of full rings or arcs. "Popcorn" calcification was defined as well-defined rings and arc-shaped calcifications overlaying amorphous areas of calcification.

RESULTS

Eleven cases met the inclusion criteria. The study population consisted of four mixed breed dogs over 20 kg, two small mixed breed dogs less than 20 kg, one Labrador retriever, one boxer, one German shepherd dog, one corgi and one shih-tzu. Median age was 10 years (range 4 to 13 years), median weight was 24 kg (range 6.5 to 45 kg) and there were five spayed females, five neutered males and one intact male. The mean duration of clinical signs before presentation was 5.5 weeks (range 1 to 12 weeks) with common clinical signs being stertorous breathing, nasal discharge (including epistaxis) and sneezing. No dog presented with neurologic signs. All dogs had thoracic radiographs and abdominal ultrasounds. One dog had multiple pulmonary nodules with a differential diagnosis of metastatic neoplasia *versus* granulomatous disease on thoracic radiographs. There were no significant ultrasonographic findings or evidence of abdominal metastasis reported in any of the dogs.

CT findings are listed in Table 2. Eight of the 11 (72%) tumours had areas of calcification. Most of these had multiple types of calcification patterns but were grouped based on the predominant type. Six of 11 (55%) had popcorn calcification and two of 11 (18%) had ring-and-arc calcification. Ring-and-arc calcification was seen as small, well-defined, ring or arc-shaped areas of increased attenuation (greater than 100 HU) within the soft tissue-attenuating masses (Fig 1). Popcorn calcification had similar, discrete areas of increased attenuation overlying or mixed with amorphous areas of increased attenuation (Fig 2).

One of 11 (9%) dogs had mild lymphadenopathy of the right retropharyngeal lymph node (ipsilateral to the tumour). The remaining 10/11 (91%) dogs all had mandibular and retropharyngeal lymph nodes within normal limits for size and contrast enhancement. None of the 11 dogs had abnormal contrast enhancement of the mandibular or retropharyngeal lymph nodes. All dogs had mandibular lymph node aspirates performed at the time of the CT scan. There was no cytologic evidence of nodal metastasis identified.

Histologically, all neoplasms were definitively classified as chondrosarcoma. They consisted of coalescing, poorly demarcated, non-encapsulated lobules of monomorphic mesenchymal spindyloid to polygonal cells embedded in extracellular matrix. The matrix varied from scant and myxoid supporting cells in sheets to abundant and chondroid surrounding cells in individual lacunae. Foci of mineralisation were apparent in some areas of chondroid differentiation (Fig 3).

DISCUSSION

In this retrospective study, the appearance of nasal chondrosarcoma was consistent with some of the previously reported characteristics of canine nasal neoplasia on CT (Burk 1992). The tumours were mildly heterogeneously contrast-enhancing, expansile or destructive, soft tissue masses with variable areas of increased density within abnormal soft tissue. However, not previously reported in the veterinary chondrosarcoma literature, but known in humans, is ring-and-arc or popcorn calcification in 8/11 (73%) chondrosarcomas.

Popcorn calcification has been described as a feature of multilobular osteochondrosarcoma (MLO) in dogs but not with chondrosarcoma. In human medicine, popcorn calcification is considered typical of the broader group of chondroid matrix tumours. While these two tumours could appear similar on imaging, location could help differentiate between a chondrosarcoma and MLO. MLOs tend to occur on flat bones of the skull and have a well-defined ovoid appearance (Forrest 2015).

Ring-and-arc calcification was not previously reported as a CT feature of canine nasal chondrosarcoma or other neoplasia.

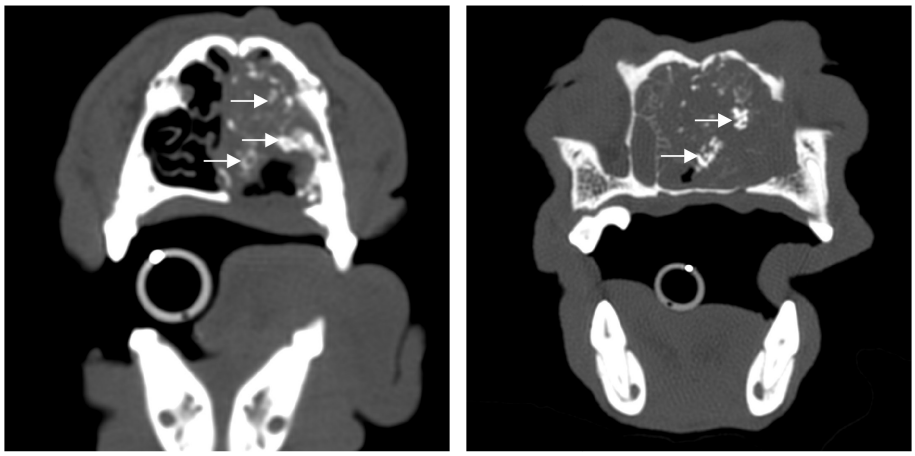

FIG 1. Transverse images of the rostral (A) and caudal (B) nasal cavity in bone windows illustrating "ring and arc" calcification (arrows)

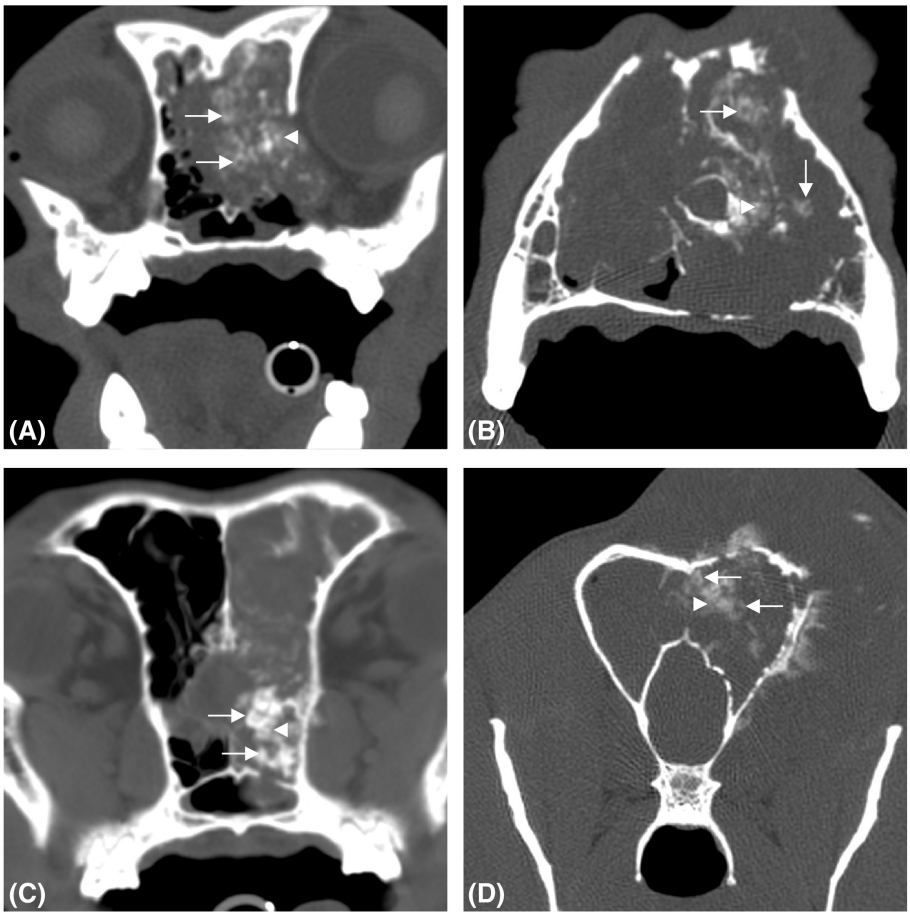

FIG 2. Transverse images of the caudal nasal cavity (A), rostral nasal cavity (B) and frontal sinus (C, D) in bone windows illustrating "popcorn" calcification with amorphous areas of calcification (arrow heads) and well-defined ring-and-arc shapes (arrows)

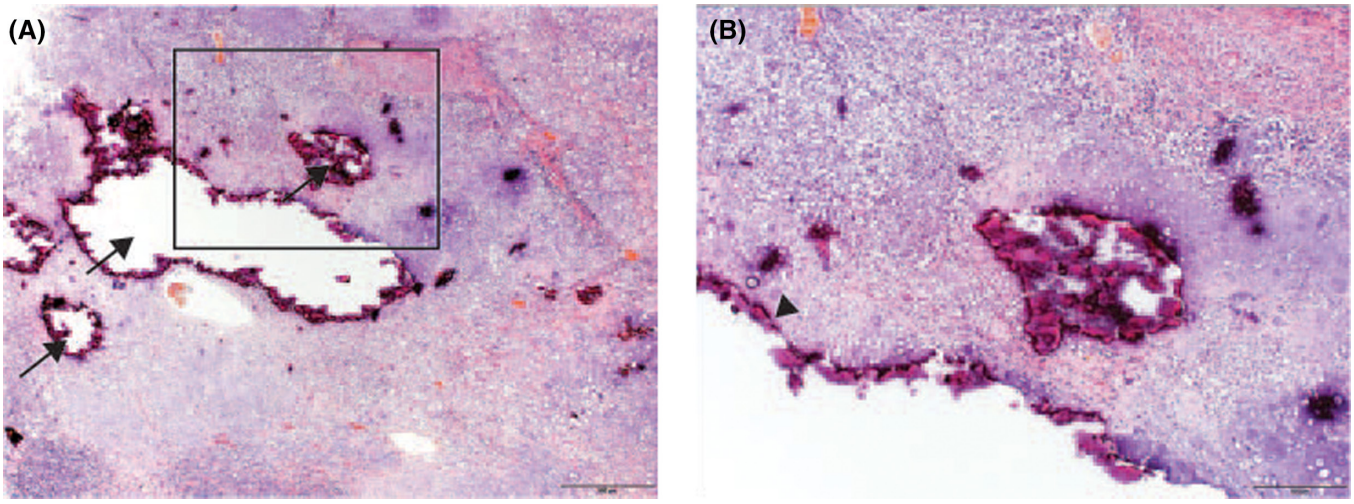

FIG 3. Photomicrographs of a nasal chondrosarcoma. (A) x40: foci of calcification (arrow) surrounded by chondroid cells in extracellular matrix. Haematoxylin and eosin stain; bar=500 µm. (B) x100: Inset of (A). Haematoxylin and eosin stain; bar=200 µm

The only report of chondroid tumour mineralisation patterns on imaging, was in a study of the radiographic appearance of nasal and non-nasal chondrosarcoma in 35 dogs, in which "flecks of calcification scattered irregularly throughout the tumour" were apparent on radiographs in four dogs with non-nasal chondrosarcoma (Brodey *et al.* 1974).

In humans, radiographic and CT findings suggestive of chondrosarcoma are well documented and exhibit a classic appearance due to chondroid matrix mineralisation (Murphey *et al.* 2003). The tumours are described as soft tissue masses with stippled and amorphous areas of calcification referred to as ring-and-arc calcification or popcorn calcification (Huijun *et al.*

2015). Ring-and-arc calcification is characteristic of chondroid lesions and is due to endochondral mineralisation of multiple hyaline cartilage nodules (Rassekh *et al*. 1996, Murphey *et al*. 2003). Popcorn calcification has similar ring-and-arc shapes over a background of amorphous calcification. In the human literature, well-defined ring-and-arcs are seen in lower grade tumours (Murphey *et al*. 1998). These patterns are often considered pathognomonic for chondral calcification, but there are reports of ring-and-arc calcification being attributed to osteoblastomas and calcium pyrophosphate dehydrate crystal deposition disease (Murphey *et al*. 1996, 2007). Popcorn calcification is also seen in pulmonary hamartomas and fibroadenomas of the breast (Roche *et al*. 2002). Nevertheless, rings, arcs or popcorn calcification are strongly suggestive of a chondroid lesion in humans.

In this study, ring-and-arc or popcorn calcification was found only in stage 4 and stage 3 chondrosarcomas. All six canine chondrosarcoma tumours with predominately popcorn calcification were of the highest stage: stage 4. The two tumours with predominantly ring-and-arc calcification were either stage 4 or stage 3. While the large proportion of stage 4 tumours in this study may explain why the calcification patterns were more common in this stage as opposed to being related to the actual tumour grade, in humans mineralisation has been related to the tumour histologic grade rather than tumour stage.

The major limitation of this study is that only nasal chondrosarcomas were evaluated. Any conclusions drawn from the calcification patterns can only be correlated to nasal chondrosarcomas. Other limitations of the study include its retrospective nature, small sample size, inclusion of only two reviewers who were not blinded and the subjective nature of the descriptive analysis. The histopathology results were definitive for chondrosarcoma and therefore are not in question or considered a limitation of this study. A larger scale study with comparison of potential calcification patterns within other nasal tumour types and a larger number of blinded reviewers would help further evaluate the findings of our descriptive study. Additionally, reviewing non-nasal chondrosarcoma CTs for similar calcifications could help determine if the calcification pattern can be attributed to the tumour type, as it is in people.

In conclusion, while histopathology is required for a definitive diagnosis, as in human medicine, "ring-and-arc" or "popcorn" calcification in canine nasal tumours may suggest prioritising chondrosarcoma as a diagnosis.

Conflict of interest

None of the authors of this article has a financial or personal relationship with other people or organisations that could inappropriately influence or bias the content of the paper.

References

Adams, W. M., Kleiter, M. M., Thrall, D. E., *et al*. (2008) Prognostic significance of tumour histology and computed tomographic staging for radiation treatment response of canine nasal tumours. *Veterinary Radiology* **50**, 330-335

Brodey, R. S., Misdorp, W., Riser, W. H., *et al*. (1974) Canine skeletal chondrosarcoma: a clinicopathologic study of 35 cases. *Journal of the American Veterinary Medical Association* **165**, 68-78

Burk, R. (1992) Computed tomographic imaging of nasal disease in 100 dogs. *Veterinary Radiology* **33**, 177-180

Burningham, Z., Hashibe, M., Spector, L., *et al*. (2012) The epidemiology of sarcoma. *Clinical Sarcoma Research* **2**, 14

Dernell, W. S., Ehrhart, N. P., Straw, R. C., *et al*. (2007) Tumours of the skeletal system. In: Withrow and MacEwen's Small Animal Clinical Oncology. Saunders Elsevier, St. Louis, MO, USA. pp 540-582

Forrest, L. (2015) The Cranial Nasal Cavities: Canine and Feline, in Textbook of Veterinary Diagnostic Radiology. 6th edn. Elsevier, St. Louis, MO, USA. pp 183-202

Huijun, H., Xiaomao, X., Weike, Z., *et al*. (2015) Low-to moderate-grade myxoid chondrosarcoma in the craniofacial region: CT and MRI findings in 13 cases. *Oral Radiology* **32**, 81-89

Inwards, C. Y. (2007) Update on cartilage forming tumours of the head and neck. *Head and Neck Pathology* **1**, 67-74

MacEwen, E. G., Withrow, S. J. & Patnaik, A. K. (1977) Nasal tumours in the dog: retrospective evaluation of diagnosis, prognosis and treatment. *Journal of the American Veterinary Medical Association* **170**, 45-48

Murphey MD, Andrews CL, Flemming DJ, Temple HT, Smith WS, Smirniotopoulos. Primary tumours of the spine: radiologic pathologic correlation. *Radiographics* **16**:1159-1163, 1996.

Murphey, M. D., Flemming, D. J., Boyea, S. R., *et al*. (1998) Enchondroma versus chondrosarcoma in the appendicular skeleton: differentiating features. *Radiographics* **18**, 1213-1237

Murphey, M. D., Walker, E. A., Wilson, A. J., *et al*. (2003) Imaging of primary chondrosarcoma: radiologic-pathologic correlation. *Radiographics* **23**, 1245-1278

Murphey, M. D., Vidal, J. A., Fanburg-Smith, J. C., *et al*. (2007) Imaging of synovial chondromatosis with radiographic-pathologic correlation. *Radiographics* **27**, 1465-1488

Patnaik, A. K. (1989) Canine sinonasal neoplasms: clinicopathological study of 285 cases. *Journal of the American Animal Hospital Association* **25**, 103-114

Patnaik, A. K., Lieberman, P. H., Erlandson, R. A., *et al*. (1984) Canine sinonasal skeletal neoplasms: chondrosarcoma and osteosarcomas. *Veterinary Pathology* **21**, 475-482

Popovitch, C. A., Weinstein, M. J., Goldschmidt, M. H., *et al*. (1994) Chondrosarcoma: a retrospective study of 97 dogs (1987-1990). *Journal of the American Animal Hospital Association* **30**, 81-85

Rassekh, C. H., Nuss, D. W., Kapadia, S. B., *et al*. (1996) Chondrosarcoma of the nasal septum: skull base imaging and clinicopathologic correlation. *Otolaryngology and Head and Neck Surgery* **115**, 29-37

Roche, C. J., O'Keefe, P. O., LEE, W. K., *et al*. (2002) Selection from the buffet of food signs in radiology. *Radiographics* **22**, 1369-1384

Rozeman, L. B., Cleton-Jansen, A. M. & Hogendoorn, P. C. W. (2006) Pathology of primary malignant bone and cartilage tumours. *International Orthopaedics* **30**, 437-444

Sones, E., Smith, A., Schleis, S., *et al*. (2013) Survival times for canine intranasal sarcomas treated with radiation therapy: 86 cases (1996-2011). *Veterinary Radiology* **54**, 194-201

Thrall, D. E., Robertson, I. D., McLOad, D. A., *et al*. (1989) A comparison of radiographic and computed tomographic findings in 31 dogs with malignant nasal cavity tumours. *Veterinary Radiology* **30**, 59-66